



# Stafne's bone defect with bicortical perforation: a need for modified classification system

Astha Chaudhry<sup>1,2</sup>

Received: 16 March 2020 / Accepted: 14 June 2020

© Japanese Society for Oral and Maxillofacial Radiology and Springer Nature Singapore Pte Ltd. 2020

## Abstract

Stafne's bone defect (SBD) or salivary gland-related bone defects are asymptomatic bone cavities in the mandible caused by impingement by the salivary glandular tissue. The major salivary glands, particularly the submandibular gland, are in close relation with the mandible and their impingement can produce radiolucent defects on the lingual cortical surface of the mandible. Submandibular gland-related bone defects or depressions are referred as posterior lingual variant of SBD. These are asymptomatic and appear as well-defined radiolucent areas that are incidentally discovered on panoramic radiographs. Three-dimensional imaging may be required to evaluate the extent of cortical involvement and to determine the content of the cavity or defect. Usually, these defects are seen in the lingual cortices and are lined by cortex that causes a smooth radiopaque periphery. The involvement of both the buccal and lingual cortices by the defect is extremely uncommon. Literature has classified cases with buccal cortical expansion but buccal cortical perforation has not been described and classified. This case report describes this uncommon presentation of the salivary gland bone defect and through an in-depth literature review proposes a modification in the existing classification system.

**Keywords** Bone defect · Mandibular bone depression · Stafne's bone cyst · Salivary gland depression

## Introduction

Submandibular salivary gland lies in close relation with the medial surface of the body of mandible that usually produces a depression on the bone surface. It is seen as a radiolucent area with ill-defined borders just below the mandibular canal and referred to as submandibular gland fossa.

Stafne's bone defect (SBD) is the actual defect or cavity in the mandible that occurs due to the cortex bowing inward into the medullary space of the mandible. The cortex mostly remains intact separating the medullary space of the mandible from the soft tissues in the glandular space. Since these SBDs are lined by cortex, they appear as well-defined radiolucent areas with a smooth radiopaque rim [1].

SBD was first described by Stafne in 1942 [2] and was termed as "bone cavities situated near the angle of

mandible". The term latent cyst for these was described by Rushton as they appeared cystic on radiographs and were inactive [3]. These have fairly constant location between the inferior alveolar canal and inferior cortical border of mandible at or near the groove made by the facial artery where it crosses the mandible. They are usually unilateral and may show varying shapes with smooth corticated or punched out periphery. They are mostly unilocular but rarely may be multilocular. Generally, they show only lingual cortical involvement, and involvement of both the cortices is very rare. Only a few cases of bicortical involvement have been reported till date [4]. The present case report highlights an unusual presentation of the bicortical defect and also highlights the importance of classification of these defects for their appropriate management.

## Case report

A 60-year-old male patient was referred to the dental OPD with the complaint of missing teeth. The clinical examination of the patient did not reveal any significant abnormality except for completely edentulous maxillary and mandibular

✉ Astha Chaudhry  
dr.asthac@gmail.com

<sup>1</sup> Department of Oral Medicine and Radiology, Faculty of Dental Sciences, SGT University, Gurugram, Haryana, India

<sup>2</sup> Present Address: Gurugram, India

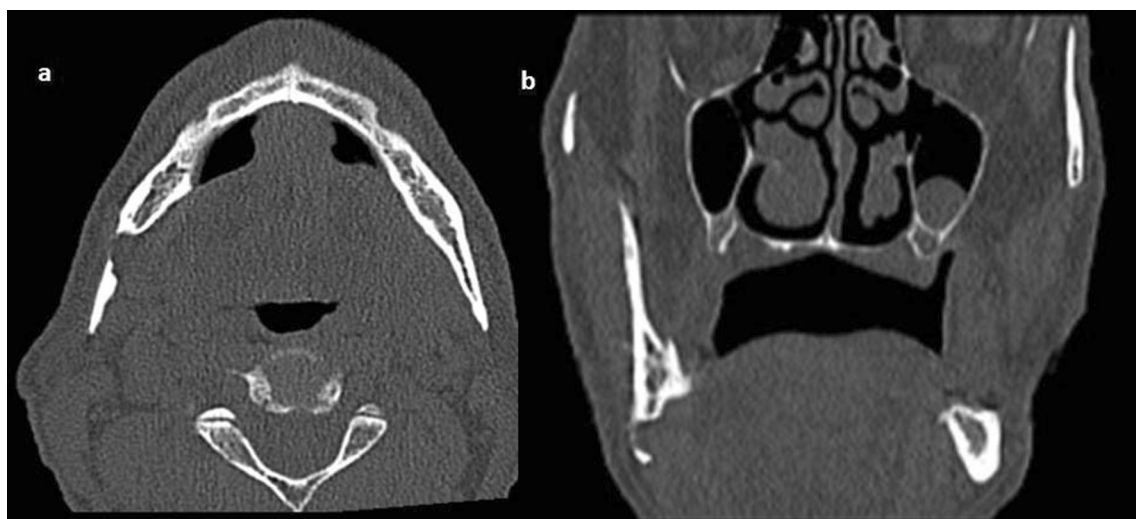arches. The medical history was positive for hypertension for 15 years. The dental treatment plan included an implant-supported prosthetic rehabilitation, and to evaluate the quality and quantity of bone for implant placement, Dentascan was advised. The axial and coronal sections revealed a well-defined hypodense lesion in the right mandibular angle region with complete loss of lingual cortex and extending to involve the buccal cortex leading to its perforation. The lesion showed smooth borders. No expansion of buccal cortical plate was noted (Fig. 1).

The paraxial section showed the presence of lesion below the inferior alveolar canal with no alteration in the canal itself (Fig. 2). The 3D reconstruction also showed the buccal

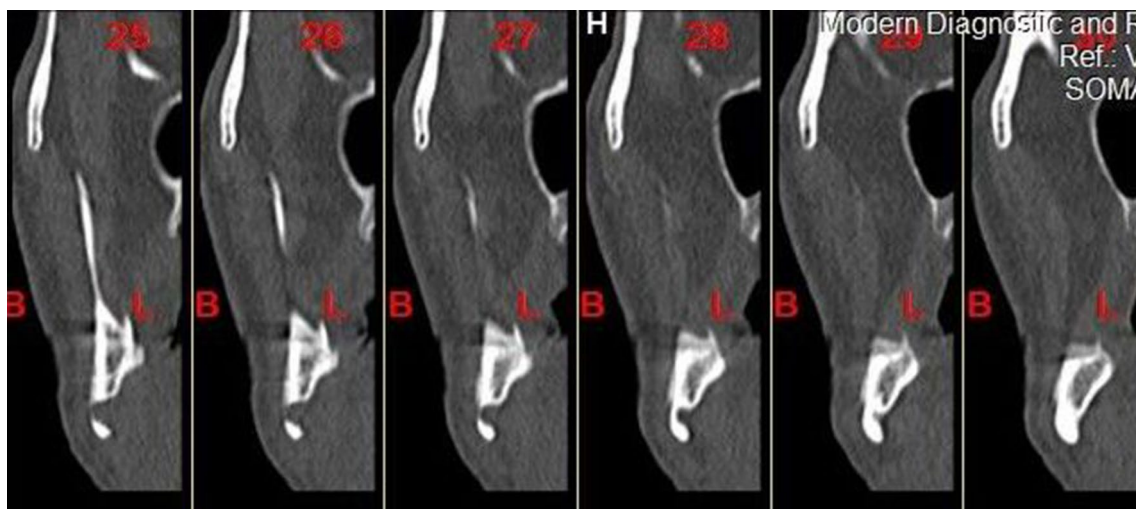perforation without expansion and a greater area of bone defect on the lingual cortex (Fig. 3).

On retrograde clinical examination, no hollowness was felt during the bidigital extraoral and intraoral examination. There was no history of pain or paresthesia.

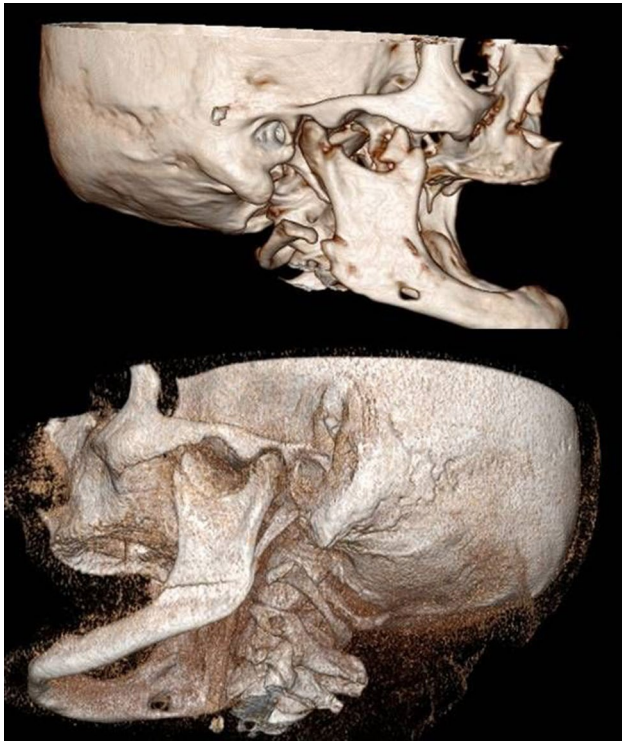The asymptomatic clinical picture and typical location of the lesion below the inferior alveolar canal along with its density consistent with the salivary gland tissue and adipose tissue (– 30 to 60 HU) favored the diagnosis of SBD with bicortical involvement. Since the patient was asymptomatic, no active treatment was given for SBD. However, implant-supported prosthetic rehabilitation for the patient was continued and the patient was kept on regular follow-up.



**Fig. 1** The axial (a) and coronal (b) showing the posterior lingual variant of Stafne's bone defect with significant erosion of buccal cortex leading to perforation but without any evidence of expansion



**Fig. 2** The cross-sectional images showing the location of the defect below the mandibular canal and leading to buccal cortical perforation



**Fig. 3** The 3-D reconstruction showing the buccal cortical perforation without expansion and a greater area of bone defect on the lingual cortex

## Discussion

Mandibular bone depressions due to salivary glands have been described by various terminologies like aberrant or ectopic salivary gland defect, static bone defect or cavity, idiopathic bone cavity, latent bone cyst, lingual mandibular bone depression, developmental bone defect and SBD [5]. Instead of aberrant or ectopic salivary gland tissue, they are usually caused by the impingement of bone by the normal salivary gland tissue present in that region. They are mostly detected in 5th and 6th decades of life with an incidence of 0.3% in adults [1] and show a male predilection with a male/female ratio of 6:1. These lesions are not congenital and may show some degree of growth to a size of 1–3 cm; hence, termed as developmental defects that are relatively static or latent [6, 7]. These lesions are usually unilateral but may be bilateral. Literature has described a unilocular radiographic appearance with variable shapes like round, ovoid, triangle or heart shape and rare multilocular variants have also been reported [8].

A classification of these submandibular bone defects has been given by Ariji et al. [9] in 1993 taking into account the depth and content of the cavity as determined by computed tomography.

Type I: Cavity depth is limited to the medullary portion of the mandible.

Type II: Cavity depth reaches the buccal cortex of the mandible but does not cause its expansion.

Type III: Cavity depth reaches the buccal cortex of the mandible and causes its expansion.

According to content, they were classified as

Type F: Cavity is filled with fat.

Type S: Cavity is filled with soft tissue (lymph node, vessel, connective tissue, etc.).

Type G: Cavity is filled with part of the submandibular gland.

In the present reported case, the cavity depth was reaching up to the buccal cortex but no expansion of the cortex was noted. Instead, perforation of the buccal cortical plate was seen and it was Type G according to the content. This could not be classified into the traditional classification system proposed by Ariji et al. Since no case report of SBD with terminology as ‘buccal cortical perforation’ has ever been reported in the literature, an attempt was made to review all the reported cases of SBD.

A thorough literature search through PUBMED database was done using the keywords ‘Stafne’s Cyst’, ‘Stafne Bone defect’, ‘Stafne’s Bone cavity’, ‘Salivary gland depression’ and ‘Static bone cavity’. A total of 149 articles were found and 126 of them were related to SBD in the form of case series or reports. About 17 articles from foreign languages were found but for two of them, we were able to find the full text and attempt was made to look out the images for evaluation of the relationship of SBD with the buccal cortex. One of these articles showed buccal cortical perforation and the other showed Type II defect as per Ariji et al.

All the 126 articles were reviewed to find out if 3-D imaging has been done. 3-D imaging was pertinent for the identification of the involvement of the buccal cortical plate. The articles for which full text or 3D images could not be found were excluded from the review. Out of the 126 articles, only 59 articles showed the application of 3-D imaging including CT, CBCT or MRI. Only the articles that presented with CT or CBCT or MRI images of the SBD were selected and reviewed to identify the involvement of buccal cortex even if the authors have failed to report it. Among these, only 3 reports have mentioned the involvement of the buccal cortex in the title itself. Rest of the articles have not commented on the buccal cortical involvement in the title. However, on reviewing their text and the CT/CBCT/MRI images, the involvement of the buccal cortex was evident. A total of 30 articles with 47 different cases showed varying types of associations with the buccal cortex (Table 1). For a clear

**Table 1** Review of literature of reported cases of Stafne’s bone defect with bicortical involvement

S.no.	Author	Year	Modality used	Type of Stafne’s defect	Buccal cortical erosion	Buccal cortical perforation	Buccal cortical expansion	Buccal cortical expansion and perforation
1.	Ariji et al. [9]	1993	CT	Posterior lingual			3 cases	
2.	Philipsen et al. [10]	2002	CT Sialography	Posterior lingual			1 case	
3.	Smith et al. [13]	2005	CBCT and MRI	Bilateral anterior	1 case			
4.	Shimizu M et al. [11]	2006	CT	Posterior lingual			3 cases	
5.	Segev et al. [14]	2006	CT and MRI	Posterior lingual	1 case			
6.	Campos et al. [15]	2010	CT and scintigraphy	Posterior lingual			1 case	
7.	Li B et al. [16]	2011	CBCT	Posterior lingual				1 case
8.	A. P. Münevveroğlu et al. [17]	2012	CBCT	Posterior lingual	1 case	1 case		
9.	Etoz et al. [18]	2012	CT	Posterior lingual	1 case			
10.	Saglam et al. [19]	2013	CT and MRI	Posterior lingual			1 case	
11.	Prechtel et al. [20]	2013	CT	Posterior lingual		1 case		
12.	Boffano et al. [21]	2013	CBCT	Posterior lingual	1 case			
13.	Aparicio et al. [22]	2014	CT and MRI	Posterior lingual		1 case		
14.	Aydin et al. [23]	2014	CBCT	Posterior lingual	1 case			
15.	Schneider et al. [24]	2014	CT(Dentascan) and MRI	Posterior lingual				1 case
16.	Taysi et al. [25]	2014	CBCT	Anterior lingual				1 case
17.	Sumer et al. [26]	2015	CT	Posterior lingual				1 case
18.	More et al. [4]	2015	CT	Posterior lingual		1 case		2 cases
19.	Ertas et al. [27]	2015	CBCT and MRI	Posterior lingual		1 case		
20.	Miloglu et al. [28]	2015	CBCT	Posterior lingual(multilocular)		1 case		
21.	Schaerlaken et al. [29]	2015	CT and MRI	Posterior lingual	1 case			
22.	Ji Young Song [30]	2016	CT	Anterior lingual				1 case
23.	Lee et al. [31]	2016	CT	Posterior Lingual	1 case			
24.	Hulbrock et al. [32]	2016	CBCT	Posterior lingual	1 case			
25.	Chen et al. [33]	2016	CBCT	Medial ramus variant	1 case			
26.	Yildirim D et al. [34]	2017	CBCT	Posterior lingual Anterior lingual	3 cases 1 case			
27.	Kaya et al. [35]	2018	MRI	Posterior lingual			1 case	
28.	Liu et al. [12]	2018	CBCT	Posterior lingual			8 cases	
29.	Unsal et al. [36]	2019	CBCT and MRI	Posterior lingual				1 case
30.	Chen MH et al. [37]	2019	CBCT	Posterior lingual	1 case			

understanding, the association of the defect with the buccal cortex was categorized into four types (Table 1):

- SBD with buccal cortical erosion;
- SBD with buccal cortical perforation;
- SBD with buccal cortical expansion;
- SBD with buccal cortical expansion and perforation.

Among the articles included, Philipsen et al. [10] have described about 69 new cases from Japan and discussed their clinical and radiological profile. In the text, no information about buccal cortical involvement of the 69 reported cases has been discussed although CT sialographic image of case showing buccal cortical expansion has been displayed in the article. Hence, for the present review, only one case out of the 69 cases was included. In another analysis of 32 cases by Shimizu et al. [11], only three cases have been mentioned to

have buccal cortical expansion without any data pertaining to buccal cortical erosion or perforation. Hence, only three cases have been included in the category of buccal cortical expansion. In a separate analysis of CBCT features of lingual mandibular depression by Liu et al. [12] in 2018, the relationship of lingual depression to the buccal cortex was categorized on the same lines by Arijji et al. as separated, contacted and expanded. So, only eight cases that showed buccal cortical expansion were included. There was again no data about buccal cortical erosion or perforation. In their report of eight cases, one case showed perforation on CBCT but that was refuted by the smooth hyperechoic appearance on ultrasound.

Among all the 47 cases reviewed, about 31.9% (15 cases) showed SBD extending up to the buccal cortex and causing its erosion without any perforation or expansion.

About 12.7% (6 cases) showed extensive buccal cortical involvement leading to the perforation of the buccal cortex without any expansion. And if the present discussed case is included, it makes up to 7 cases of SBD with buccal cortical perforation.

About 38.29% (18 cases) exhibited buccal cortical expansion and 17% (8 cases) showed extensive buccal cortical expansion leading to its perforation.

The original classification by Arijji et al. was proposed based on the CT findings of 16 SBDs. The report has mentioned about seven cases of Type II variety. However, there were no supporting images to identify if buccal erosion was evident in any of them. Arijji et al. also reported three cases of Type III defect with buccal cortical expansion but due to the absence of supporting images, the presence of minute buccal cortical perforation if existing could not be found from the report. Hence, only three cases have been included in the review under the category of SBD with buccal cortical expansion.

An argument that can be proposed against the classification by Arijji et al. is the limitation for the nomenclature of buccal ramus variant of SBD (parotid gland depressions) which initiates on the buccal cortical surface and progresses lingually. But these are extremely rare and not enough cases have been reported in the literature to warrant a classification. Thus, considering the observations from the literature review, the proposed modifications in the existing system of classification are as follows (Fig. 4):

Type I: Cavity depth is limited to the medullary portion of the mandible.

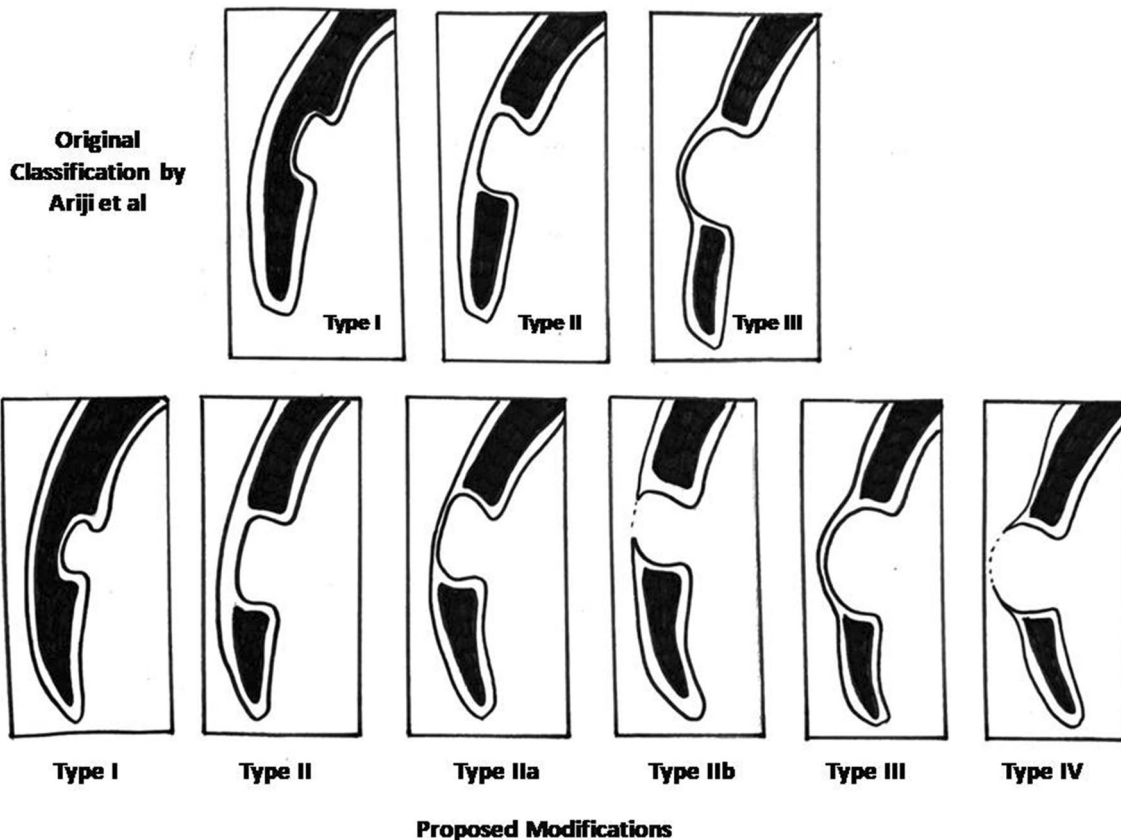


Fig. 4 Pictorial comparison of the classification by Arijji et al. and the proposed modifications

Type II: Cavity depth reaches the buccal cortex of the mandible but does not cause its expansion.

Type IIa: Cavity depth reaches the buccal cortex of mandible and causes its erosion.

Type IIb: Cavity depth reaches the buccal cortex of mandible and causes its perforation.

Type III: Cavity depth reaches the buccal cortex of the mandible and causes its expansion.

Type IV: Cavity depth reaches the buccal cortex and causes its expansion and perforation.

The author suggests that this modification of the classification will be more comprehensive and will characterize and incorporate all the lingual SBDs and will thus help in effective monitoring and follow-up of these lesions.

The most accepted and logical etiologic concept for SBD is the focal resorption of bone due to pressure exerted by the variably hypertrophic/hyperplastic fibrotic gland due to old age [10]. The fibrotic gland can exert pressure sufficient to cause resorption of the lingual cortex with extensions into the buccal cortex as well. A coexisting vascular alteration could also have a synergistic effect as seen in our patient who was an elderly male with a long-term history of hypertension.

The management of SBD usually involves watchful radiographic follow-up since these are usually asymptomatic and do not have major complications. Biopsy of the lesion usually reveals salivary gland tissue, adipose tissue, lymph nodes or muscle. Advanced imaging is required to determine the exact extent of the lesion and to exclude other pathologies. Three-dimensional imaging providing information about the content of the cavity would help in confirming the diagnosis and avoiding the need for surgery. Classifying these lesions aids in their better characterization as well as in monitoring their follow-up. The change in the characteristics of these lesions on subsequent follow-ups may alert the clinician on the specific growth potential of the lesion and may assist in planning the appropriate surgical treatment.

**Funding** The authors declare that no funding agencies sponsored the work.

### Compliance with ethical standards

**Conflict of interest** The authors declare that there are no potential areas of conflict of interest.

**Ethical statement** This article does not contain any studies with human or animal subjects performed by any of the authors.

## References

1. Wood NK, Goaz PW. Solitary cyst like radiolucencies not necessarily contacting teeth: differential diagnosis of oral and maxillofacial lesions. 5th ed. Mosby: Elsevier; 2006. p. 315–318.
2. Stafne E. Bone cavities situated near the angle of the mandible. *J Am Dent Assoc.* 1942;29:1969–72.
3. Worth HM. Odontomes and cysts of the jaws: principles and practice of oral radiologic interpretation. 1st ed. Chicago: Year book; 1963. p. 416–417.
4. More CB, Das S, Gupta S, Patel P, Saha N. Stafne's bone cavity: a diagnostic challenge. *J Clin Diag Res.* 2015;9(11):ZD16–19.
5. White SC, Pharoah MJ. Developmental disturbances of the face and jaws. *Oral Radiology: Principles and Interpretation.* 4th ed. United States, St. Louis: Mosby; 2000. p. 598–600.
6. Hansson L. Development of a lingual mandibular bone cavity in an 11 year old boy. *Oral Surg.* 1980;49:376–8.
7. Wolf J, Mattila K, Ankukuriniemi O. Development of a Stafne mandibular bone cavity: report of a case. *Oral Surg.* 1986;61:519–21.
8. Langlais RP, Langland OE, Nortje CJ. Diagnostic imaging of the jaws. 2nd ed. Baltimore: Williams & Wilkins; 1995. p. 241–248.
9. Ariji E, Fujiwara N, Tabata O, Nakayama E, Kanda S, Shiratsuchi Y, et al. Stafne's bone cavity: classification based on outline and content determined by computed tomography. *Oral Surg Oral Med Oral Pathol.* 1993;76(3):375–80.
10. Philipsen H, Takata T, Reichart P, Sato S, Sueti Y. Lingual and buccal mandibular bone depressions: a review based on 583 cases from a world-wide literature survey, including 69 new cases from Japan. *Dentomaxillofac Radiol.* 2002;31:281–90.
11. Shimizu M, Osa N, Okamura K, Yoshiura K. CT analysis of the Stafne's bone defects of the mandible. *Dentomaxillofac Radiol.* 2006;35(2):95–102.
12. Liu L, Kang BC, Yoon SJ, Lee JS, Hwang SA. Radiographic features of lingual mandibular bone depression using dental cone beam computed tomography. *Dentomaxillofac Radiol.* 2018;47(6):20170383.
13. Smith MH, Brooks SL, Eldevik OP, Helman JI. Anterior mandibular lingual salivary gland defect: a report of a case diagnosed with cone-beam computed tomography and magnetic resonance imaging. *Oral Surg Oral Med Oral Pathol Oral Radiol Endod.* 2007;103(5):e71–e7878.
14. Segev Y, Puterman M, Bodner L. Stafne bone cavity—magnetic resonance imaging. *Med Oral Patol Oral Cir Bucal.* 2006;11:E345–E347347.
15. Flores Campos PS, Oliveira JA, Dantas JA, de Melo DP, Pena N, Santos LA, et al. Stafne's defect with buccal cortical expansion: a case report. *Int J Dent.* 2010;2010:515931. <https://doi.org/10.1155/2010/515931>.
16. Li B, Long X, Cheng Y, Wang S. Cone beam CT sialography of Stafne bone cavity. *Dentomaxillofac Radiol.* 2011;40:519–23.
17. Münevveroğlu AP, Aydın KC. Stafne bone defect: report of two cases. *Case Rep Dent.* 2012;2012:654839. <https://doi.org/10.1155/2012/654839>.
18. Etoz M, Etoz OA, Sahman H, Sekerci AE, Polat HB. An unusual case of multilocular Stafne bone cavity. *Dentomaxillofac Radiol.* 2012;41:75–8.
19. Saglam M, Salihoglu M, Sivrioglu AK, Kara K. Multimodality imaging of Stafne bone defect. *BMJ Case Rep.* 2013;2013:bcr2013009483. <https://doi.org/10.1136/bcr-2013-009483>.
20. Prechtl C, Stockmann P, Neukam FW, Schlegel KA. Enlargement of a Stafne cyst as an indication for surgical treatment—a case report. *J Craniomaxillofac Surg.* 2013;41(3):270–3.

21. Boffano P, Gallesio C, Daniele D, Rocchia F. An unusual trilobite Stafne bone cavity. *Surg Radiol Anat*. 2013;35:351–3. <https://doi.org/10.1007/s00276-012-1043-7>.
22. Herranz-Aparicio J, Figueiredo R, Gay-Escoda C. Stafne's bone cavity: an unusual case with involvement of the buccal and lingual mandibular plates. *J Clin Exp Dent*. 2014;6(1):e96–e9999.
23. Aydin U, Oguz Y. Stafne bone cavity incidentally “Twice” diagnosed on panoramic radiographs. *J Oral Maxillofac Radiol*. 2014;2:26–9.
24. Schneider T, Filo K, Stadlinger B, Locher M, Kruse AL, Lübbers HT. An atypical Stafne cavity-multi-chamber bone lesion with buccal expansion. A case report. *Swiss Dent J*. 2014;124(5):545–55.
25. Taysi M, Ozden C, Cankaya B, Olgac V, Yıldırım S. Stafne bone defect in the anterior mandible. *Dentomaxillofac Radiol*. 2014;43:20140075.
26. Sumer M, Acikgoz A, Uzun C, Gunhan O. An unusual case of large, destructive Stafne bone cavity with computed tomography findings. *J Oral Maxillofac Radiol*. 2015;3:28–30.
27. Ertas ET, Atici MY, Kalabalik F, Ince O. Investigation and differential diagnosis of Stafne bone cavities with cone beam computed tomography and magnetic resonance imaging: report of two cases. *J Oral Maxillofac Radiol*. 2015;3:92–6.
28. Miloğlu Ö, Sekerci AE, Yasa Y, Dagistan S. Unilateral bone cavities situated near the angle of the mandibula. *J Craniofac Surg*. 2015;26(1):e27–e2828.
29. Schaerlaken DA, Dom M, Hintjens J, Chapelle K, Dekeyzer S, Vanhoenacker FM. Stafne Bone Cavity. *J Belg Soc Radiol*. 2015;98(3):137–8.
30. Song J-Y. Anterior Stafne bone cyst mimicking periapical cyst: a case report. *J Dent Rehab Appl Sci*. 2016;32(3):209–13.
31. Lee JI, Kang SJ, Jeon SP, Sun H. Stafne bone cavity of the mandible. *Arch Craniofac Surg*. 2016;17(3):162–4.
32. Hulbrock JM, Maitland R, Gray RG. Unusual large Stafne bone pseudocyst: a case report. *J Mass Dent Soc*. 2016;65(3):22–4.
33. Chen CA, Ahn Y, Odell S, Mupparapu M, Graham DM. Developmental salivary gland depression in the ascending mandibular ramus: a cone-beam computed tomography study. *Imag Sci Dent*. 2016;46(3):223–7.
34. Yildirim D, Gormez O, Bozdemir E, Aydin U, Yilmaz O, Aydogmus Erik A, et al. Imaging characteristics of Stafne bone cavity: pictorial essay. *Iran J Radiol*. 2017;14(2):e40701.
35. Kaya M, Ugur KS, Dagli E, Kurtaran H, Gunduz M. Stafne bone cavity containing ectopic parotid gland. *Braz J Otorhinolaryngol*. 2018;84(5):669–72.
36. Ünsal G, Karapınar G, Özcan I, Koca RB, Olgaç V, Orhan K. Stafne Bone Cavity with expansion at posterior mandible: a case report and review of the literature. *Oral Maxillofacial Surg Cases*. 2020;6(1):100132.
37. Chen MH, Kao CT, Yu-Fong Chang J, Wang YP, Wu YH, Chiang CP. Stafne bone defect of the molar region of the mandible. *J Dent Sci*. 2019;14(4):378–82.

**Publisher's Note** Springer Nature remains neutral with regard to jurisdictional claims in published maps and institutional affiliations.